

# NONLETHAL SCREENING OF BAT-WING SKIN WITH THE USE OF ULTRAVIOLET FLUORESCENCE TO DETECT LESIONS INDICATIVE OF WHITE-NOSE SYNDROME

Gregory G. Turner,<sup>1</sup> Carol Uphoff Meteyer,<sup>2,11,12</sup> Hazel Barton,<sup>3</sup> John F. Gumbs,<sup>4</sup> DeeAnn M. Reeder,<sup>5</sup> Barrie Overton,<sup>6</sup> Hana Bandouchova,<sup>7</sup> Tomáš Bartonička,<sup>8</sup> Natálie Martínková,<sup>9,10</sup> Jiri Pikula,<sup>7</sup> Jan Zukal,<sup>8,9</sup> and David S. Blehert<sup>2</sup>

<sup>1</sup> Pennsylvania Game Commission, 2001 Elmerton Avenue, Harrisburg, Pennsylvania 17710, USA

<sup>2</sup> US Geological Survey, National Wildlife Health Center, 6006 Schroeder Road, Madison, Wisconsin 53711, USA

<sup>3</sup> Department of Biology, University of Akron, 185 East Mill Street, Akron, Ohio 44325, USA

<sup>4</sup> BATS Research Center, 107 Meadow View Court, Shohola, Pennsylvania 18458, USA

<sup>5</sup> Department of Biology, Bucknell University, 1 Dent Drive, Lewisburg, Pennsylvania 17756, USA

<sup>6</sup> Department of Biology, Lock Haven University, 301 West Church Street, Lock Haven, Pennsylvania 17745, USA

<sup>7</sup> Department of Ecology and Diseases of Game, Fish and Bees, University of Veterinary and Pharmaceutical Sciences Brno, Palackeho 1/3, 612 42 Brno, Czech Republic

<sup>8</sup> Department of Botany and Zoology, Masaryk University, Kotlarska 2, 611 37 Brno, Czech Republic

<sup>9</sup> Institute of Vertebrate Biology, Academy of Sciences of the Czech Republic, Květná 8, 603 65 Brno, Czech Republic

<sup>10</sup> Institute of Biostatistics and Analyses, Masaryk University, Kamenice 3, 625 00 Brno, Czech Republic

<sup>11</sup> Current address: US Geological Survey National Center, Environmental Health, 12201 Sunrise Valley Drive, Reston, Virginia 20192, USA

<sup>12</sup> Corresponding author (email: cmeteyer@usgs.gov)

**ABSTRACT:** Definitive diagnosis of the bat disease white-nose syndrome (WNS) requires histologic analysis to identify the cutaneous erosions caused by the fungal pathogen *Pseudogymnoascus* [formerly *Geomyces*] *destructans* (*Pd*). Gross visual inspection does not distinguish bats with or without WNS, and no nonlethal, on-site, preliminary screening methods are available for WNS in bats. We demonstrate that long-wave ultraviolet (UV) light (wavelength 366–385 nm) elicits a distinct orange–yellow fluorescence in bat-wing membranes (skin) that corresponds directly with the fungal cupping erosions in histologic sections of skin that are the current gold standard for diagnosis of WNS. Between March 2009 and April 2012, wing membranes from 168 North American bat carcasses submitted to the US Geological Survey National Wildlife Health Center were examined with the use of both UV light and histology. Comparison of these techniques showed that 98.8% of the bats with foci of orange–yellow wing fluorescence ( $n=80$ ) were WNS-positive based on histologic diagnosis; bat wings that did not fluoresce under UV light ( $n=88$ ) were all histologically negative for WNS lesions. Punch biopsy samples as small as 3 mm taken from areas of wing with UV fluorescence were effective for identifying lesions diagnostic for WNS by histopathology. In a nonlethal biopsy-based study of 62 bats sampled (4-mm diameter) in hibernacula of the Czech Republic during 2012, 95.5% of fluorescent ( $n=22$ ) and 100% of nonfluorescent ( $n=40$ ) wing samples were confirmed by histopathology to be WNS positive and negative, respectively. This evidence supports use of long-wave UV light as a nonlethal and field-applicable method to screen bats for lesions indicative of WNS. Further, UV fluorescence can be used to guide targeted, nonlethal biopsy sampling for follow-up molecular testing, fungal culture analysis, and histologic confirmation of WNS.

**Key words:** Bat, Chiroptera, dermatomycosis, fungal infection, *Pseudogymnoascus* (*Geomyces*) *destructans*, ultraviolet (UV) fluorescence, white-nose syndrome.

## INTRODUCTION

White-nose syndrome (WNS) is caused by the psychrophilic fungus *Pseudogymnoascus* [formerly *Geomyces*] *destructans* (*Pd*) (Lorch et al. 2011; Minnis and Lindner 2013). Mortality from *Pd* infection has been confirmed for six species of North American bats, including little

brown myotis (*Myotis lucifugus*), northern myotis (*Myotis septentrionalis*), Indiana myotis (*Myotis sodalis*), Eastern small-footed myotis (*Myotis leibii*), tricolored bat (*Perimyotis subflavus*), and big brown bat (*Eptesicus fuscus*) (Turner et al. 2011). *Pd* has also been isolated from bats in Europe (Puechmaille et al. 2011a), with documentation of characteristic invasive

lesions diagnostic for WNS (Pikula et al. 2012); unusual mortality has not been reported among European bats infected by *Pd* (Martínková et al. 2010; Puechmaile et al. 2011b; Sachanowicz et al. 2014).

White-nose syndrome is the first invasive cutaneous ascomycosis reported in mammals. Currently, histopathology is required to diagnose WNS (Meteyer et al. 2009). To collect an adequate sample of wing membrane (skin) to conduct a thorough histopathologic analysis, euthanasia is typically required. A rapid, field-applicable, and nonlethal technique to identify presumptive WNS would reduce the need to euthanize bats to obtain a diagnosis. Such a technique would additionally serve to enhance ability to expand diagnostic activities to assess the presence of disease in new species and additional regions of the world, and to screen bats rapidly to determine efficacy of potential mitigation strategies.

Since the historic observation in 1925 that typical fungal dermatophyte infections fluoresce under long-wave ultraviolet (UV) light, this technique has been used as aid for diagnosing keratinaceous fungal infections, including ringworm in domestic animals (Koeing and Schneckenburger 1994) and tinea capitis in humans (Margarot and Deveze 1925). Applying this technique to wing membranes of bats with suspect WNS, long-wave (366–385 nm) UV light was shown to be a rapid, reliable, and field-applicable diagnostic tool for preliminary identification of WNS in bat-wing membranes and an accurate guide for targeted, nonlethal biopsy sampling for subsequent histologic confirmation.

## MATERIALS AND METHODS

### Paired assessments with the use of UV illumination and histology in the laboratory

The fluorescence of bat wings in response to long-wave UV light was compared to the histologic gold standard for diagnosing WNS. Three different UV light sources were used in these studies described below; a hand-held flashlight for quick detection of fluorescence

in the laboratory, a stationary Wood's lamp for photography in the laboratory, and a stationary 9-watt UV light for transillumination in the field. These light sources are described in detail below and all had wavelengths of 366–385 nm.

The wings of 168 bats of 11 species submitted to the US Geological Survey National Wildlife Health Center Madison, Wisconsin, USA (USGS NWHC) from 21 states between March 2009 and April 2012 were evaluated for fluorescence with the use of a hand-held 51-LED 385-nm UV flashlight (model 7202 UV-385 nm, LED Wholesalers, Hayward, California, USA) in a darkened room. Laboratory personnel wore UV-protective eyewear when illuminating bat wings and the same individual performed all visual assessments for fluorescence to ensure consistency. Photography was performed in a darkened room with the use of a Nikon (Tokyo, Japan) D80 digital SLR camera (F-stop 3.3, ISO 200, shutter speed 8 sec) with an AF 60 mm lens with no filter and a Wood's lamp (366 nm; BLAK-RAY Model UVL-56, San Gabriel, California, USA) mounted approximately 13 cm above the bat at a 35–40-degree angle as the sole light source to illuminate the outstretched wing from above.

After external examination, the entire membrane was removed from a wing for histologic evaluation with the use of periodic acid–Schiff stain as described by Meteyer et al. (2009). All samples were coded for impartial histologic assessment for WNS and later compared with the UV-fluorescence status. Fisher's exact test (SigmaPlot 11.0, Systat Software, Inc., San Jose, California, USA) was used to determine whether there was a relationship between fluorescence and WNS lesions.

### UV fluorescence for targeted sample collection for WNS confirmation

A field study was conducted to determine if UV fluorescence could provide a preliminary diagnosis of WNS and guide nonlethal collection of wing tissue to determine WNS status by histopathology. Torpid bats were removed from roosts during surveys, captured in flight while exiting hibernacula, or found dead at hibernacula entrances. Methods and equipment used in the field for UV illumination of bat wings were the same in the US and the Czech Republic. White or UV light was used to illuminate wing membrane of bats either from above (light on the same side as the person viewing) or below (transilluminating the wing with the light source on the opposite side of viewing). A GloBox (Artograph, Delano,

Minnesota, USA) was used for white light transillumination, and a field-portable 9-watt 368-nm fluorescent light (WTC 9L-110, Way Too Cool, from Fluorescents.com [www.fluorescents.com]) was used for UV transillumination. The use of white light illumination was discontinued after the effectiveness of UV fluorescence was established. During transillumination of live bats in the field, bats were kept in the dark, placed on the working surface of the light unit with wings extended. Photographs were then taken of wings with the use of a Canon (Melville, New York, USA) EOS 350D digital SLR camera (F-stop 5–10, ISO 200, and shutter speeds 0.5–30 sec) equipped with an EFS 18–55 mm or EF 100-mm lens with 58-mm ultraviolet filter (in Pennsylvania); or a Nikon D300 digital SLR camera (F-stop 5.3–5.8, ISO 1000, and shutter speeds 0.15–0.4 sec) with AF NIKKOR 28–80-mm lens (in the Czech Republic). Cameras were mounted on a tripod (Fig. 1A). Bats were rapidly processed to reduce handling time and minimize stress. To prevent cross-contamination, field equipment was either sanitized between bats or covered with a disposable plastic sheet (Shelley et al. 2013). Dedicated “clean” equipment was used in uninfected sites to decrease risk for inadvertent introduction of a pathogen.

To characterize ability of field biologists to assess WNS-related fluorescence accurately, wings of *M. lucifugus* ( $n=6$ ) from two Pennsylvania sites known to harbor bats with WNS were collected in 2010 and 2011, transilluminated with UV light, and multiple 1-cm<sup>2</sup> regions of wing membrane were outlined on each bat with permanent marker and labeled as either fluorescent ( $n=14$ ) or non-fluorescent ( $n=13$ ). Marked wings were then photographed during UV transillumination, and bats were euthanized by isoflurane overdose. Carcasses were shipped overnight (chilled) to the NWHC for histologic evaluation as described above.

To evaluate the effectiveness of UV transillumination-guided biopsy sampling for WNS testing, four sizes of sterile biopsy punches (McKesson, Richmond, Virginia, USA) were used. One biopsy punch of each size (3, 4, 5, and 6 mm) was used to collect areas of wing fluorescence from each of five bats providing 20 skin biopsy samples of different sizes for histopathology evaluation.

Single biopsy samples (4-mm diameter) guided by UV transillumination were collected from each of 62 live bats of six different species in the Czech Republic as they exited their hibernacula in spring 2012. Following collection, all biopsy samples were placed into individually labeled vials containing 10%

neutral buffered formalin for histopathology processing.

## RESULTS

The effectiveness of long-wave UV light for detection of lesions consistent with WNS was tested with the use of a combination of field and laboratory studies. Roosting bats with distinct foci of orange–yellow fluorescence could be identified when bats were illuminated from above with UV light (Fig. 1B), but this was infrequent. Wings of bats extended and illuminated from above with white light occasionally showed indistinct white fungal growth (Fig. 1C), but evidence of fungal growth or wing damage was not apparent when the wings of the bats were transilluminated with white light (Fig. 1D). However, when long-wave UV light was used to illuminate outstretched bat wings from above (Fig. 1E) or transilluminate wings from below (Fig. 1F), distinct areas of orange–yellow fluorescence were seen. Photography in the laboratory was most successful with a Wood’s lamp illuminating the wing from above (Fig. 1E). When photographing live bats under field conditions, UV transillumination (as opposed to UV illumination from above) provided the most expedient and reliable approach for detecting the orange–yellow fluorescence (Fig. 1F). When white fungal growth was seen on the wings of bats illuminated from above with white light, it corresponded to the pattern of orange–yellow fluorescence seen during UV transillumination (Fig. 1C, F). Computer magnification of digital images enhanced the ability to detect isolated pinpoint areas of fluorescence.

### Paired assessments with the use of UV illumination and histology in the laboratory

Of the 168 bats submitted to the NWHC for diagnostic investigation, 80 had areas of characteristic orange–yellow fluorescence when the wings were illuminated from above with a hand-held 51-LED 385-nm UV flashlight; 79 of these were histologically positive and one histologically negative for

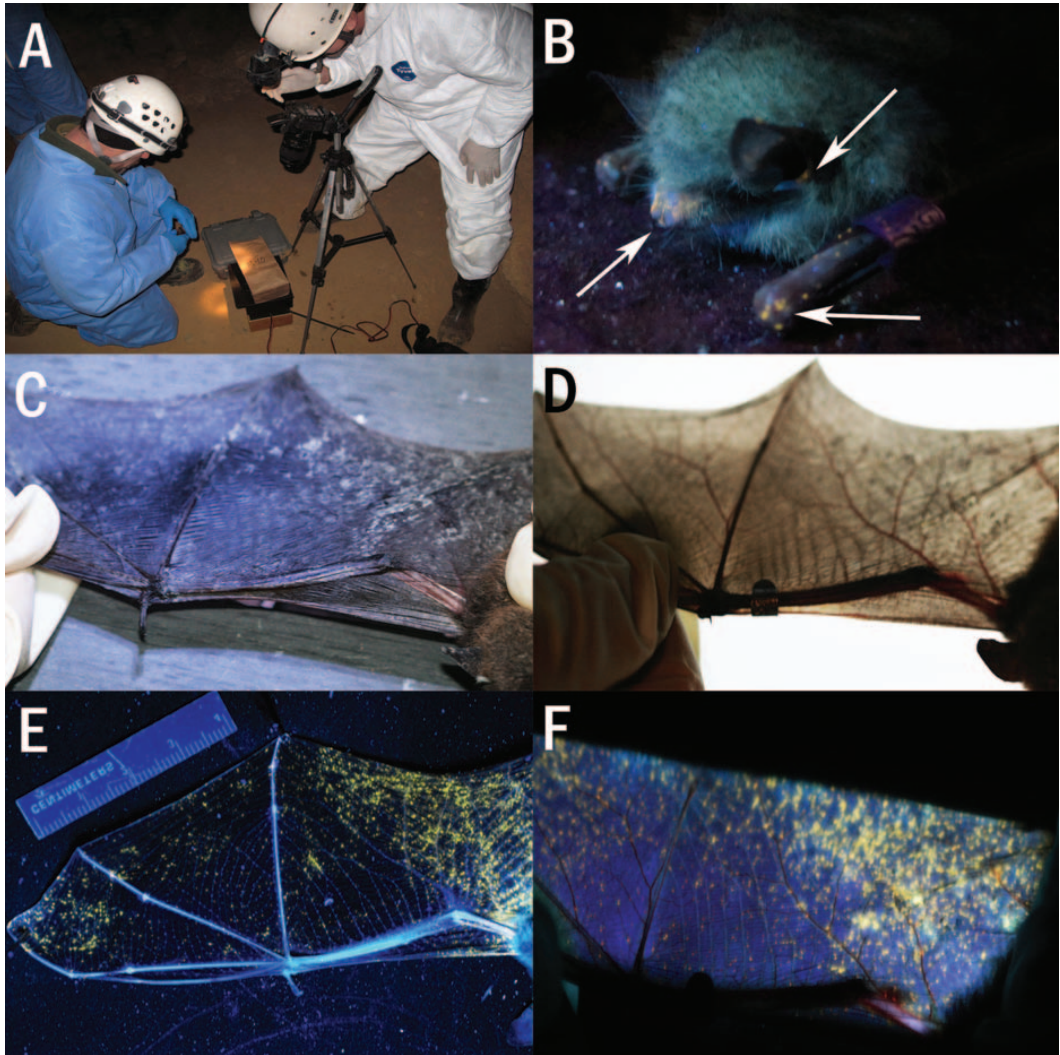


FIGURE 1. Long-wave ultraviolet (UV) and white-light illumination of lesions associated with white-nose syndrome. All photographs are from bats of the US; blurring in photos of live bats in C, D, and F is due to animal movement during long exposure. (A) Camera in cave, mounted on tripod directed at platform constructed to transilluminate bat wings with UV light (photo by Craig Stihler with permission). (B) Points of orange–yellow fluorescence (arrows) detected on a roosting Indiana myotis (*Myotis sodalis*) following surface illumination with a field-portable 9-watt 368-nm fluorescent UV light (photo by Tina Cheng with permission). (C) Wing from live little brown myotis (*Myotis lucifugus*) lit from above in cave with white light shows dispersed pattern of fungal growth. (D) White-light transillumination of wing from the live bat in C shows no obvious pattern of fungal infection or wing damage. (E) Wing from dead tricolored bat (*Perimyotis subflavus*) lit from above with hand-held 51 LED 385-nm UV flashlight shows points of orange–yellow fluorescence. (F) Transillumination of wing from live bat in C with the use of a field-portable 9-watt 368-nm fluorescent UV light. The pattern of orange–yellow fluorescence follows the distribution of surface fungal growth seen in C.

WNS (98.8% agreement between UV and histopathology assessments; Table 1). The 88 bats that were UV-fluorescence negative were all histologically negative for WNS

(Table 1). There was a strong Fisher's exact test association between UV fluorescence and WNS lesions ( $P < 0.001$ ) in these 168 bats.

TABLE 1. Summary of paired ultraviolet (UV) fluorescence and histologic analyses for bats from North America and UV-targeted biopsy-based study for bats from Europe.

Bat species	Positive		Negative		Total
	Fluorescence	Histology	Fluorescence	Histology	
US (whole carcasses)					
<i>Myotis lucifugus</i>	59	58	40	41	99
<i>Eptesicus fuscus</i>	1	1	1	1	2
<i>Myotis leibii</i>	1	1	0	0	1
<i>Myotis septentrionalis</i>	5	5	7	7	12
<i>Perimyotis subflavus</i>	11	11	16	16	27
<i>Myotis grisescens</i>	0	0	7	7	7
<i>Myotis velifer</i>	0	0	11	11	11
<i>Myotis sodalis</i>	0	0	1	1	1
<i>Myotis yumanensis</i>	0	0	1	1	1
<i>Myotis austroriparius</i>	0	0	3	3	3
<i>Tadarida brasiliensis</i>	0	0	1	1	1
Unidentified <i>Myotis</i> sp.	3	3	0	0	3
Total	80	79	88	89	168
Czech Republic (biopsy samples)					
<i>Myotis myotis</i>	17	16	13	14	30
<i>Myotis daubentonii</i>	2	3	10	9	12
<i>Myotis nattereri</i>	2	2	5	5	7
<i>Myotis bechsteinii</i>	0	0	6	6	6
<i>Myotis alcathoe</i>	0	0	5	5	5
<i>Myotis emarginatus</i>	1	1	1	1	2
Total	22	22	40	40	62

Of the 88 bats that were UV-fluorescence negative and histologically negative, 22 had microscopic evidence of fungal colonization in the superficial keratin layer of wing skin that was morphologically distinct from WNS, and these fungi were considered to be different from *Pd*.

#### Use of UV fluorescence to target sample collection for WNS confirmation

Histologic examination of all 1-cm<sup>2</sup> targeted samples of fluorescent wing membrane collected from bats in Pennsylvania ( $n=14$ ) were positive for the dense aggregates of fungal hyphae that form cupping erosions, which define WNS (Fig. 2A, B). When these 1-cm<sup>2</sup> skin samples encompassed single, pinpoint dots of fluorescence, microscopic examination identified individual fungal erosions diagnostic for WNS as small as 20–40  $\mu$ m in diameter (Fig. 2B). Nine of 13 1-cm<sup>2</sup> regions of wing membrane marked as nonfluorescent had no cupping erosions when examined microscopically.

The remaining 4 of 13 nonfluorescent samples examined microscopically had a single fungal cupping erosion (20–40- $\mu$ m diameter) diagnostic for WNS. Retrospective computer magnification of the digital images taken in the field of these four fluorescence-negative bats subsequently detected scattered small pinpoint fluorescent areas that were not initially detected, suggesting that the reliable margin of accuracy in assessing unmagnified digital images may be lesions approximately 20–40  $\mu$ m in diameter.

The utility of nonlethal UV-targeted biopsy sampling and biopsy size requirements was evaluated with the use of wing skin samples from bats in Pennsylvania. Biopsy samples of four diameters (3, 4, 5, and 6 mm) from each of the five bat carcasses provided adequate tissue for diagnosing cupping erosions characteristic of WNS, confirming the usefulness of this nonlethal sampling technique for biopsies as small as 3 mm in diameter.

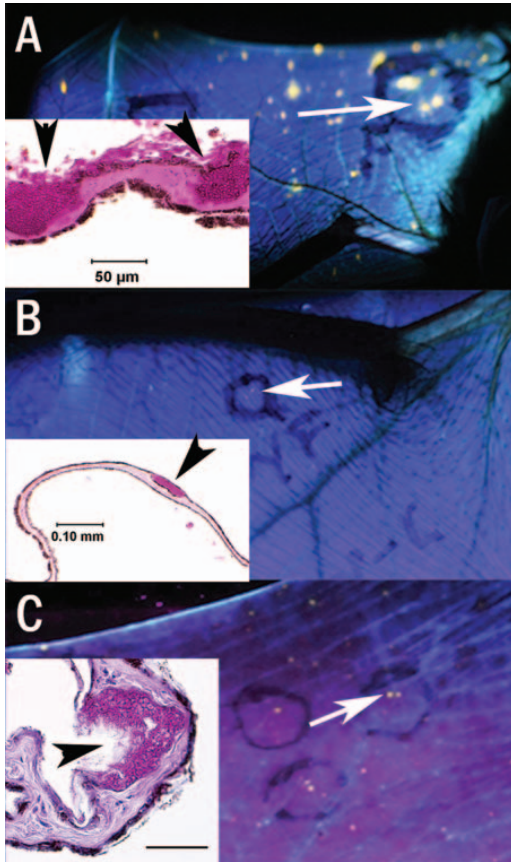


FIGURE 2. Ultraviolet fluorescence in wings of live bats (main images) and periodic acid–Schiff stained histologic sections (insets) of bat-wing skin with lesions diagnostic of white-nose syndrome; blurring in photos is due to animal movement during long exposure. (A) Black circle outlines an approximately 1-cm<sup>2</sup> area of wing from a little brown myotis (*Myotis lucifugus*), Pennsylvania, USA with foci of fluorescence (white arrow). Inset shows the histologic section of this 1-cm<sup>2</sup> area of tissue with densely packed fungal hyphae in cupping erosions (arrowheads). (B) Black circle outlines a 1-cm<sup>2</sup> area of wing from a little brown myotis, Pennsylvania, with a single fluorescent dot (white arrow). Inset shows the histologic section from this labeled area of wing membrane. (C) Black circles outline foci of fluorescence on the wing skin of a greater mouse-eared myotis (*M. myotis*) from the Czech Republic (white arrow). Inset (scale bar = 50 µm) shows the histologic section from a 4-mm biopsy sample taken from an area of fluorescence with densely packed fungal hyphae in cupping erosion (arrowhead).

Consistent with samples analyzed from North America, 21 of 22, 4-mm targeted biopsy samples from UV-fluorescent wing skin of bats from the Czech Republic also contained dense aggregates of fungal hyphae filling cupping erosions that are diagnostic for WNS (95.5% agreement between UV and histopathology assessments; Fig. 2C; Table 1). Retrospective review of digital images indicated that, for the histology-negative animal, the circled region of wing skin targeted for biopsy sampling had missed the point of fluorescence. For reporting purposes, however, this animal was classified as fluorescence-positive and histology negative. Additionally, a biopsy sample from 1 of 40 fluorescence-negative bats from the Czech Republic was positive for WNS by histology.

## DISCUSSION

The gold standard for diagnosing bat WNS is the histologic identification of aggregates of fungal hyphae that form characteristic cupping erosions and ulceration of wing membrane (Meteyer et al. 2009). The large amount of wing membrane needed to detect these lesions histologically necessitates euthanasia of the bat. Given the detrimental effect that WNS has had on bat populations (Blehert et al. 2009; Frick et al. 2010; Turner et al. 2011), detection protocols that do not require euthanasia would be advantageous.

Illumination/transillumination of wing membranes of bats with WNS with the use of long-wavelength UV light (366–385 nm) elicited a distinct orange–yellow fluorescence that correlated with the presence of fungal cupping erosions used to diagnose WNS by histopathology (Figs. 1, 2). This correlation of fluorescence to WNS histologic lesions was observed in wings from five North American and four European species of bats (Table 1), with 98.8 and 95.5% agreement between UV and histopathology assessments for bats of North America and Europe, respectively. In addition, the 22

of 88 fluorescence negative bats that had fungi along the superficial keratin of wing skin were also histologically negative for the cupping erosions that confirm WNS. This supports our hypothesis that it is the lesion of cupping erosion, characteristic of WNS, that is fluorescing with UV light, and not superficial fungal hyphae. We thus conclude that observation of orange–yellow fluorescence following illumination/transillumination of wing membranes with UV light facilitates identification of bats with WNS. *Pd* is an ascomycete fungus, as are numerous plant pathogens. Ascomycete plant pathogens change morphologically as they penetrate the plant cuticle and the distinct subsurface hyphae release novel products related to virulence at the fungal–tissue interface (Valent and Khang 2010). A similar scenario might explain fluorescence associated with the invasive lesion of WNS and not surface hyphae. Once penetration of the epidermis occurs, *Pd* hyphae may secrete novel proteins, metabolic products, and enzymes that contribute to the erosion of living tissue and fluorescence.

Bats severely affected by WNS had numerous conspicuous large, coalescing regions of fluorescence distributed over much of the wing membrane and were readily identifiable (Fig. 1E, F). In North American bats with mild WNS (Fig. 2B), as in the WNS-positive bats in Europe (Fig. 2C), the random, sparse, and pinpoint pattern of fluorescence was more difficult to see, particularly when environmental white light was not eliminated. In addition, ability to discern sparse, subtle fluorescence often varied by observer, potentially because of factors such as inexperience with the technique, red–green color blindness, or other differences in visual acuity. Because of these difficulties, UV technique may miss individual bats with mild cases of WNS. Laboratory tests including PCR for detection of *Pd* (Muller et al. 2013), culture for *Pd* (Lorch et al. 2010), and histology to diagnose WNS (Meteyer et al. 2009) continue to play a definitive role in confirming WNS. The ability to observe

sparse points of fluorescence can be enhanced by using digital photography with extended exposure time and augmentation by computer magnification of the digital images. The smallest points of fluorescence that could be visually detected with the unaided eye correlated to cupping erosions  $>20\ \mu\text{m}$  in diameter.

In addition to the demonstrated utility of long-wave UV light as a rapid field assessment technique to obtain a preliminary diagnosis for WNS, this technique can also be used to optimize nonlethal collection of small (4-mm) biopsy samples for testing by histology, PCR, or culture. Another benefit of the enhanced accuracy afforded by UV-guided sampling is the ability to identify bats with fluorescent lesions (Fig. 1B) while limiting disturbance to nonfluorescent bats within a hibernaculum. This nonlethal assessment technique can also assist natural resource managers and researchers investigating WNS by facilitating the ability to track progression of disease in individual bats and by providing the potential, in the hands of trained field personnel, to generate accurate preliminary on-site results to inform mitigation strategies more quickly. The ability to perform targeted and nonlethal sampling of bats for WNS offers a needed tool to facilitate enhanced surveillance and research for this disease.

#### ACKNOWLEDGMENTS

We thank numerous state and federal biologists for submitting diagnostic specimens to NWHC, NWHC technicians for assistance with necropsies, Nathan Ramsay (NWHC) for laboratory photography, Craig Stihler (WV DNR) and Tina Cheng (UCSC) for field photography, Colleen Patterson-Pritcher, Cynthia Hauser, Lee DeWolski, and James Sinclair for assistance in the field, and Jeff Lorch (University of Wisconsin–Madison) for helpful suggestions during preparation of this manuscript. This work was supported by the US Geological Survey, the Czech Science Foundation (P506/12/1064), and the National Speleological Society. Use of trade, product, or firm names is for descriptive purposes only and does not imply endorsement by the US government.

## Permits

In Pennsylvania, work with live bats was conducted by personnel of the Pennsylvania Game Commission in compliance with Pennsylvania Statute Title 34, Section 322, and procedures for sampling and euthanasia of bats in the US were conducted in accordance with US Geological Survey National Wildlife Health Center (NWHC) Institutional Animal Care and Use Committee Experimental Protocol 081124-A2. In the Czech Republic, live bats were sampled as they left hibernacula, and work was conducted in accordance with the Czech Academy of Sciences Ethics Committee Animal Use Protocol 169/2011 in compliance with Law 312/2008 on Protection of Animals against Cruelty adopted by the Parliament of the Czech Republic. Nonlethal sampling was in compliance with Law 114/1992 on nature and landscape protection, and was based on permits 01662/MK/2012S/00775/MK/2012, 866/JS/2012, and 00356/KK/2008/AOPK issued by the Nature Conservation Agency of the Czech Republic.

## LITERATURE CITED

- Blehert DS, Hicks AC, Behr MJ, Meteyer CU, Berlowski-Zier BM, Buckles EL, Coleman JTH, Darling SR, Gargas A, Niver R, et al. 2009. Bat white-nose syndrome: An emerging fungal pathogen? *Science* 323:227.
- Frick WF, Pollock JF, Hicks AC, Langwig KE, Reynolds DS, Turner GG, Butchkoski CM, Kunz TH. 2010. An emerging disease causes regional population collapse of a common North American bat species. *Science* 329:679–682.
- Koenig K, Schneckenburger H. 1994. Laser-induced autofluorescence for medical diagnosis. *J Fluoresc* 4:17–40.
- Lorch JM, Gargas A, Meteyer CU, Berlowski-Zier BM, Green DE, Shearn-Bochsler V, Thomas NJ, Blehert DS. 2010. Rapid polymerase chain reaction diagnosis of white-nose syndrome in bats. *J Vet Diagn Invest* 22:224–230.
- Lorch JM, Meteyer CU, Behr MJ, Boyles JG, Cryan PM, Hicks AC, Ballmann AE, Coleman JTH, Redell DN, Reeder DM, Blehert DS. 2011. Experimental infection of bats with *Geomyces destructans* causes white-nose syndrome. *Nature* 480:376–378.
- Margarot J, Deveze P. 1925. Aspect de quelques dermatoses lumière ultraparaviolette. Note préliminaire. *Bull Soc Sci Méd Biol Montpellier* 6:375–378.
- Martínková N, Bačkor P, Bartonička T, Blažková P, Červený J, Falteisek L, Gaisler J, Hanzal V, Horáček D, Hubálek Z, et al. 2010. Increasing incidence of *Geomyces destructans* fungus in bats from the Czech Republic and Slovakia. *PLoS One* 5:e13853.
- Meteyer CU, Buckles EL, Blehert DS, Hicks AC, Green E, Shearn-Bochsler V, Thomas NJ, Gargas A, Behr MJ. 2009. Histopathologic criteria to confirm white-nose syndrome in bats. *J Vet Diagn Invest* 21:411–416.
- Mimmis AM, Lindner DL. 2013. Phylogenetic evaluation of *Geomyces* and allies reveals no close relatives of *Pseudogymnoascus destructans*, comb. nov., in bat hibernacula of eastern North America. *Fungal Biol* 117:638–649.
- Muller LK, Lorch JM, Lindner DL, O'Connor M, Gargas A, Blehert DS. 2013. Bat white-nose syndrome: A real-time TaqMan polymerase chain reaction test targeting the intergenic spacer region of *Geomyces destructans*. *Mycologia* 105:253–259.
- Pikula J, Bandouchova H, Novotny L, Meteyer C, Zukal J, Irwin N, Zima J, Martínková N. 2012. Histopathology confirms white-nose syndrome in bats in Europe. *J Wildl Dis* 48:207–211.
- Puechmaile SJ, Wibbelt G, Korn V, Fuller H, Forget F, Mühlendorfer K, Kurth A, Bogdanowicz W, Borel C, Bosch T, et al. 2011a. Pan-European distribution of white-nose syndrome fungus (*Geomyces destructans*) not associated with mass mortality. *PLoS One* 6:e19167.
- Puechmaile S, Frick WF, Kunz TH, Racey PA, Voigt C, Wibbelt G, Teeling EC. 2011b. White nose syndrome: Is this emerging disease a threat to European bats? *Trends Ecol Evol* 26:570–576.
- Sachanowicz K, Stepień A, Ciechanowski M. 2014. Prevalence and phenology of white-nose syndrome fungus *Pseudogymnoascus destructans* in bats from Poland. *Cent Eur J Biol* 9:437–443.
- Shelley V, Kaiser S, Shelley E, Williams T, Kramer M, Haman K, Keel K, Barton HA. 2013. Evaluation of strategies for the decontamination of equipment for *Geomyces destructans*, the causative agent of white-nose syndrome (WNS). *J Cave Karst Studies* 75:1–10.
- Turner GG, Reeder DM, Coleman JTH. 2011. A five-year assessment of mortality and geographic spread of white-nose syndrome in North American bats, with a look at the future. *Bat Res News* 52:13–27.
- Valent B, Khang CH. 2010. Recent advances in rice blast effector research. *Curr Opin Plant Biol* 13:343–344.

Submitted for publication 3 March 2014.

Accepted 28 March 2014.